

COMMENTARY

Open Access



# The pitfalls of bedside regional cerebral oxygen saturation in the early stage of post cardiac arrest

Kosaku Kinoshita\*, Atsushi Sakurai and Shingo Ihara

## Abstract

It remains uncertain whether neuromonitoring reliably predicts outcome in adult post-cardiac arrest patients in the early stage treated with therapeutic hypothermia. Recent reports demonstrated a regional cerebral oxygen saturation of cardiac arrest patients on hospital arrival could predict their neurological outcome. There has been little discussion about the significance of regional cerebral oxygen saturation in patients with post-cardiac arrest syndrome. Amplitude-integrated electroencephalography monitoring may also provide early prognostic information for post-cardiac arrest syndrome. However, even when the initial electroencephalography is flat after the return of spontaneous circulation, good neurological outcome may still be obtainable if the electroencephalography shifts to a continuous pattern. The electroencephalography varied from flat to various patterns, such as flat, epileptic, or continuous during the first 24 h, while regional cerebral oxygen saturation levels varied even when the electroencephalography was flat. It is therefore difficult to estimate whether regional cerebral oxygen saturation accurately indicates the coupling of cerebral blood flow and metabolism in the early stage after cardiac arrest. Careful assessment of prognosis is necessary when relying solely on regional cerebral oxygen saturation as a single monitoring modality.

**Keywords:** Cardiac arrest, Post-cardiac arrest patients, Regional cerebral oxygen saturation, Amplitude-integrated electroencephalography

## Background

Recent reports demonstrate a relationship between regional cerebral oxygen saturation (rSO<sub>2</sub>) of cardiac arrest patients on hospital arrival and their neurological outcome [1, 2]. Data are insufficient to support the utility of neuromonitoring for the prediction of outcome of post-cardiac arrest syndrome (PCAS) patients [3] treated with therapeutic hypothermia. Few reports have discussed the sequential changes or physiological significance of rSO<sub>2</sub> during therapeutic hypothermia immediately after the return of spontaneous circulation (ROSC). Monitoring with electroencephalography (EEG) may be able to provide early prognostic information after ROSC in patients with therapeutic hypothermia [4, 5]. Even when EEG indicates a flat pattern in the early stage of ROSC, good neurological outcome may still be obtainable after

cardiac arrest if the EEG shifts to a continuous pattern during hypothermia [6]. Yet rSO<sub>2</sub> values tend to vary widely even when EEG patterns are flat in the early stage, which makes it difficult to estimate the neurological outcome using only a single modality for monitoring by rSO<sub>2</sub>.

In this paper we will discuss the clinical pitfalls of rSO<sub>2</sub> performed in conjunction with EEG for comatose patients after ROSC.

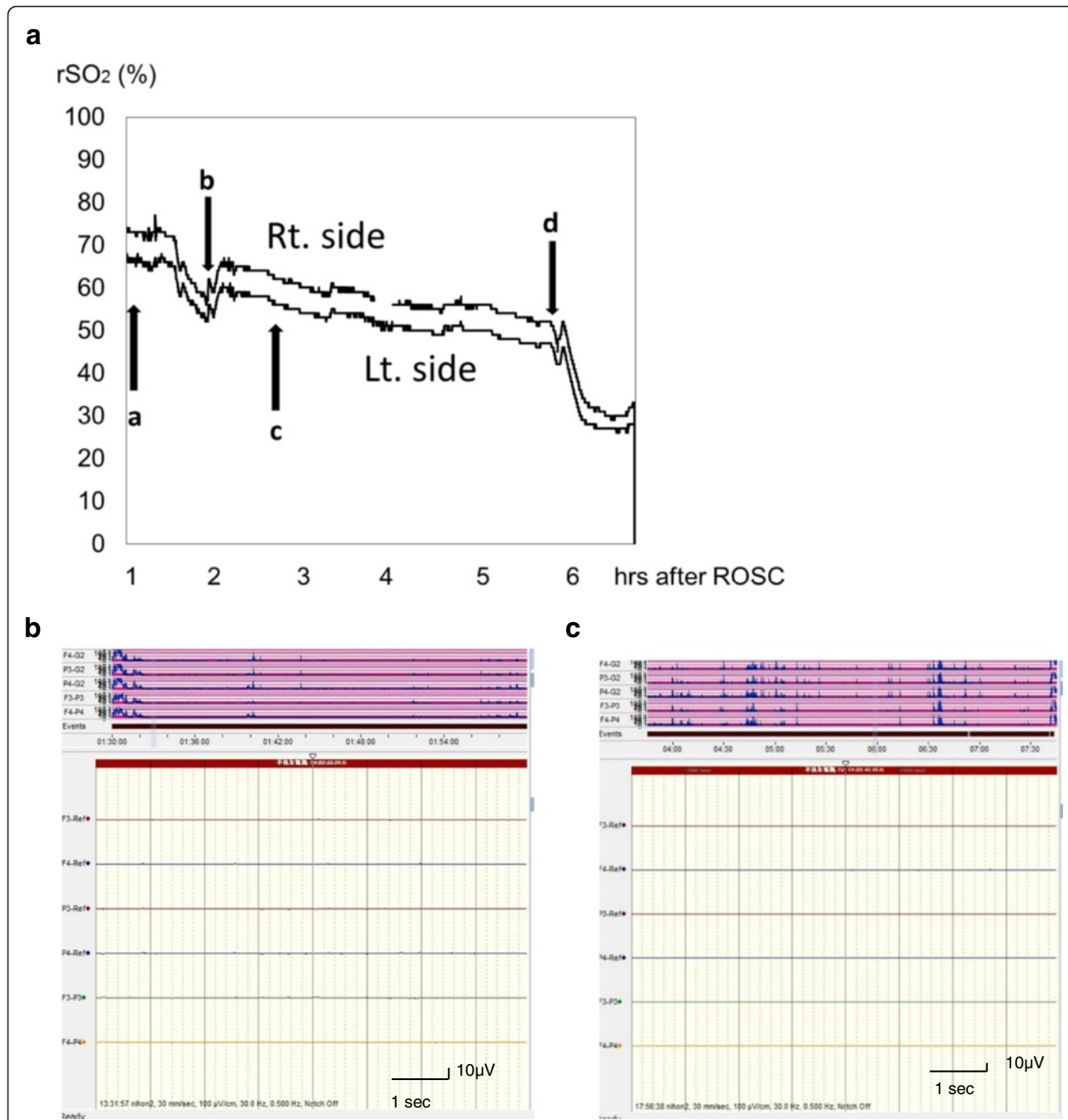
## Clinical issues of rSO<sub>2</sub> in patients with PCAS

Theoretically, rSO<sub>2</sub> can estimate the balance between the cerebral metabolic rate of oxygen (CMRO<sub>2</sub>) and cerebral blood flow (CBF), which linearly correlates with cerebral venous oxygen saturation and with CBF [7]. A host of factors such as blood pressure, blood volume, blood viscosity, oxygen delivery/metabolism, and hypo/hypercapnia lead to the vasodilation or constriction of the brain vessels when the cerebral autoregulatory mechanism responds normally, [8] and cerebral autoregulation keeps

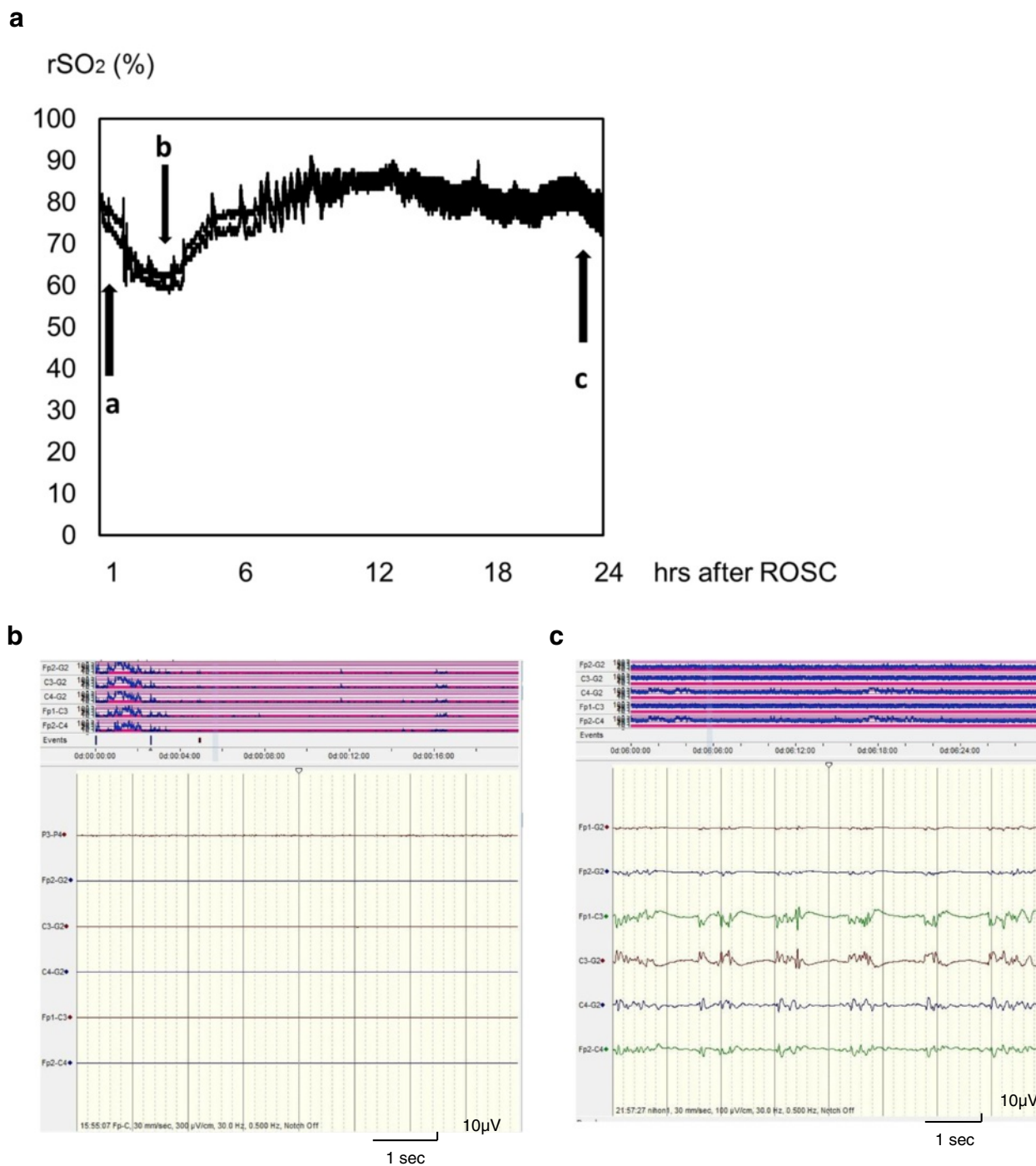
\* Correspondence: kinoshita.kosaku@nihon-u.ac.jp  
Division of Emergency and Critical Care Medicine, Department of Acute Medicine, Nihon University School of Medicine, 30-1 Oyaguchi Kamimachi Itabashi-ku, Tokyo 173-8610, Japan

the CBF constant in response to changes in these factors. However, the conditions of PCAS have many factors for dysautoregulation such as hypotension and increase or

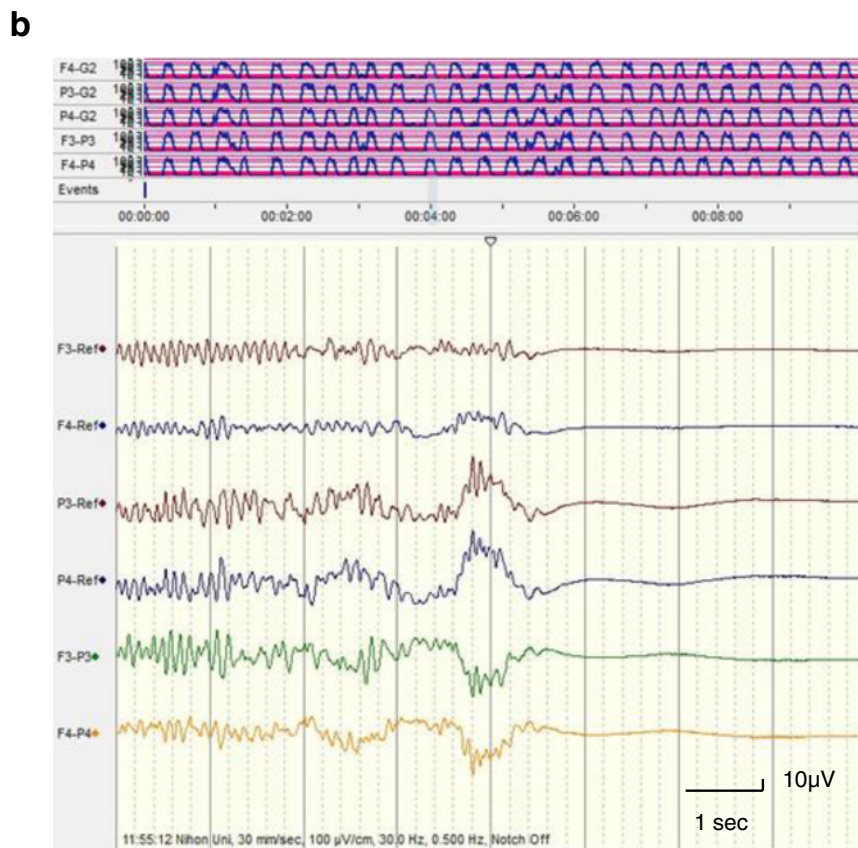
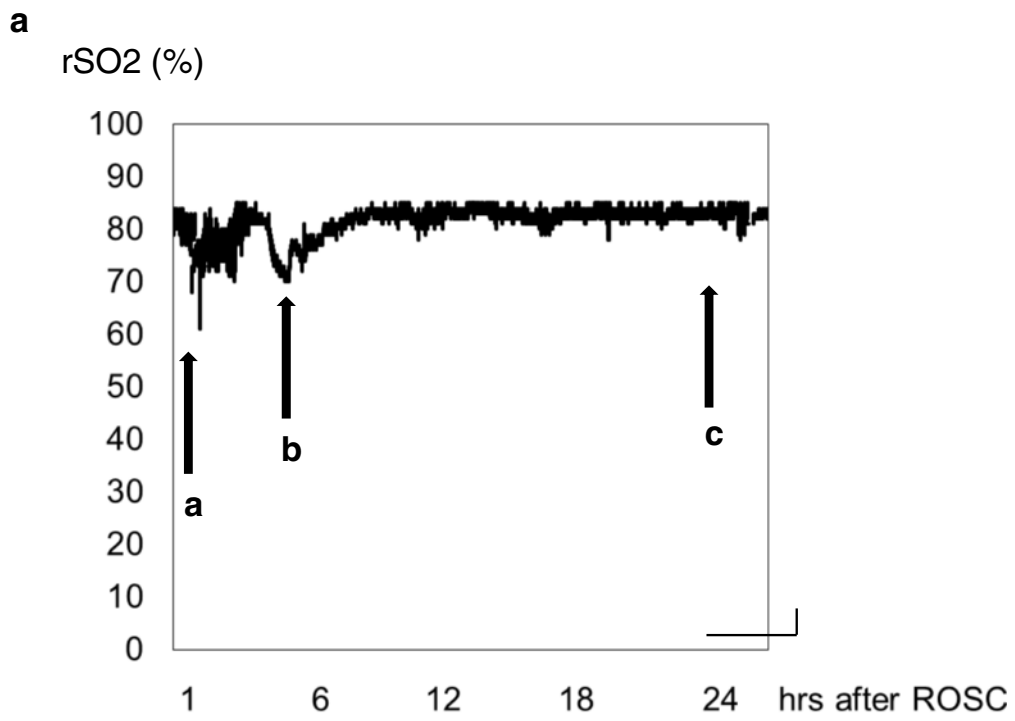
decrease in PaCO<sub>2</sub>, whereby CBF would be affected by these dysautoregulatory factors. Physicians therefore have to consider many factors when estimating rSO<sub>2</sub> values



**Fig. 1** Changes in rSO<sub>2</sub> and flat aEEG pattern in PCAS. A female in her 70s was transferred to the hospital by ambulance with an airway obstruction suffered during a meal. Her initial cardiac rhythm indicated pulseless electrical activity. The time from cardiac arrest to ROSC was 31 min. The initial rSO<sub>2</sub> value was 66–75 % (**a-a**) one hour after ROSC and the aEEG pattern was flat. Her rSO<sub>2</sub> decreased with a decline in blood pressure and rose following dopamine infusion (**a-b**). However, her rSO<sub>2</sub> gradually decreased (**a-c**) and she experienced another cardiac arrest (**a-d**) with a steep decline in rSO<sub>2</sub>. Throughout the course of treatment in the ICU, the aEEG maintained a flat pattern regardless of rSO<sub>2</sub> value (**b** and **c**). A: rSO<sub>2</sub> (%); B: aEEG, 1 h after ROSC. C: aEEG, 5 h after ROSC. Arrows: (**a**): BP 112/58 mmHg, arterial gases: PaCO<sub>2</sub> 56.8 mmHg, pH 7.189; (**b**): sBP 88 mmHg, start dopamine administration, PaCO<sub>2</sub> 42.6 mmHg, pH 7.232; (**c**): sBP 92 mmHg, arterial gases: PaCO<sub>2</sub> 39.6 mmHg, pH 7.353; **d**: cardiac arrest, start chest compression. sBP: systolic blood pressure; ROSC: return of spontaneous circulation; rSO<sub>2</sub>: regional cerebral oxygen saturation; aEEG: amplitude-integrated electroencephalography (NicoletOne™ IMI, Japan)



**Fig. 2** High rSO<sub>2</sub> and epileptic aEEG pattern in PCAS. A male in his 50s collapsed suddenly with chest pain. His initial cardiac rhythm indicated ventricular fibrillation. The time from cardiac arrest to ROSC was 24 min. The diagnosis for this patient was acute myocardial infarction. The rSO<sub>2</sub> monitoring and concurrent aEEG monitoring was commenced an hour after his collapse. His initial rSO<sub>2</sub> reading was 80 % (**a-a**) and the aEEG pattern (**b**) was flat regardless of rSO<sub>2</sub> value. Therapeutic hypothermia was commenced after the patient's ICU admission and his rSO<sub>2</sub> gradually decreased as his systemic arterial pressure fell. The patient's rSO<sub>2</sub> returned to its initial level once he received a dopamine infusion (**a-b**). The aEEG pattern changed to epileptic approximately 24 h after ROSC (**c**). The outcome for this patient was a persistent vegetative state. **a** rSO<sub>2</sub> (%); **B**: aEEG, 1 h after ROSC; **C**: aEEG, 25 h after ROSC. Arrows: a: BP 168/100 mmHg, arterial gases: PaCO<sub>2</sub> 34.7 mmHg, pH 7.441; b: BP 85/40 mmHg, start of dopamine administration, arterial gases: PaCO<sub>2</sub> 34.2 mmHg, pH 7.429; c: BP 136/88 mmHg, arterial gases: PaCO<sub>2</sub> 38.2 mmHg, pH 7.399. BP: blood pressure; ROSC: return of spontaneous circulation; rSO<sub>2</sub>: regional cerebral oxygen saturation; aEEG: amplitude-integrated electroencephalography



**Fig. 3** (See legend on next page.)



(See figure on previous page.)

**Fig. 3** High  $rSO_2$  and suppression-burst aEEG pattern in PCAS. A female in her 30s experienced cardiac arrest caused by severe bronchial asthma. Her initial cardiac rhythm indicated pulseless electrical activity. The time from cardiac arrest to ROSC was 45 min. The initial  $rSO_2$  value was 85 % (Fig. 4a-a). The aEEG pattern indicated a suppression-burst pattern 3 h after ROSC. She received a dopamine infusion after a fall in blood pressure (Fig. 4a-b). Thereafter, her  $rSO_2$  gradually returned around 80–85 % and kept constant (Fig. 1a-c) for 24 h. The outcome for this patient was brain death. aEEG measurements were taken for only 3 h after ROSC (not for 24 h) in this patient. (a):  $rSO_2$  (%); (b): aEEG, 3 h after ROSC. Arrows: a: BP 155/94 mmHg, arterial gases:  $PaCO_2$  77.2 mmHg, pH 7.125; b: BP 90/48 mmHg, arterial gases:  $PaCO_2$  44.1 mmHg, pH 7.430; c: BP 124/54 mmHg, arterial gases:  $PaCO_2$  39.4 mmHg, pH 7.455. BP: blood pressure; ROSC: return of spontaneous circulation;  $rSO_2$ : regional cerebral oxygen saturation; aEEG: amplitude-integrated electroencephalography

after cardiac arrest. The  $rSO_2$  data of brain-dead patients also demonstrates that  $rSO_2$  values do not always indicate the cerebral oxygen metabolism [9]. As seen in Fig. 1a, for example, an aEEG pattern can remain flat regardless of the  $rSO_2$  value. The  $rSO_2$  value may depend on the blood pressure, because  $CMRO_2$  is thought to be extremely suppressed when the EEG pattern is flat (Fig. 1b, c).

In the experimental model, the EEG was flat after a transient occlusion of both common carotid arteries and gradually changed from a flat to a continuous pattern after the release of the occlusion [10]. In the clinical setting, the EEG is also flat after cardiac arrest and changed from a flat to a various patterns after ROSC [6].  $CMRO_2$  was also initially depressed after ROSC [11, 12]. The balance of CBF and metabolism is significantly altered after ROSC [13] while CBF might be normal [14] or decreased [11] in the resuscitated brain during the 24 h following cardiac arrest. A previous study reports that  $CMRO_2$  is not able to predict neurological outcome in the early stage of ROSC [15]. Therefore, the estimation of injured brain or outcome using for  $rSO_2$  might need to be carefully assessed in the early stage after PCAS.

### Higher $rSO_2$ in the early stage in PCAS

Higher  $rSO_2$  values can generally be assumed to have the following pathophysiological significance: hyperemia, including reactive hyperemia (e.g., an increased level of  $PaCO_2$ ), or hyperperfusion (lower  $CMRO_2$  and higher CBF). They can also reflect hyperemia caused by severe metabolic depression due to severe brain damage in PCAS. Cerebral oxygen extraction fraction, however, can be expected to decrease in comatose patients immediately after ROSC as a consequence of the primary cerebral metabolic suppression [11]. This appears to be the case even if higher  $rSO_2$  levels are detected when the EEG is flat, given that the  $CMRO_2$  may be drastically suppressed. Figures 2 and 3 demonstrate an  $rSO_2$  level that starts at around 80 % and remains constantly high thereafter. Finally, the aEEG indicated epileptic or suppression-burst EEG patterns of a type thought to portend poor outcome. It was difficult to determine the clinical significance of the high  $rSO_2$  values in the early post-resuscitation phase [4–6]. We therefore suspect that high  $rSO_2$  values with epileptic or suppression-burst EEG

patterns indicate more severe brain damage after cardiac arrest.

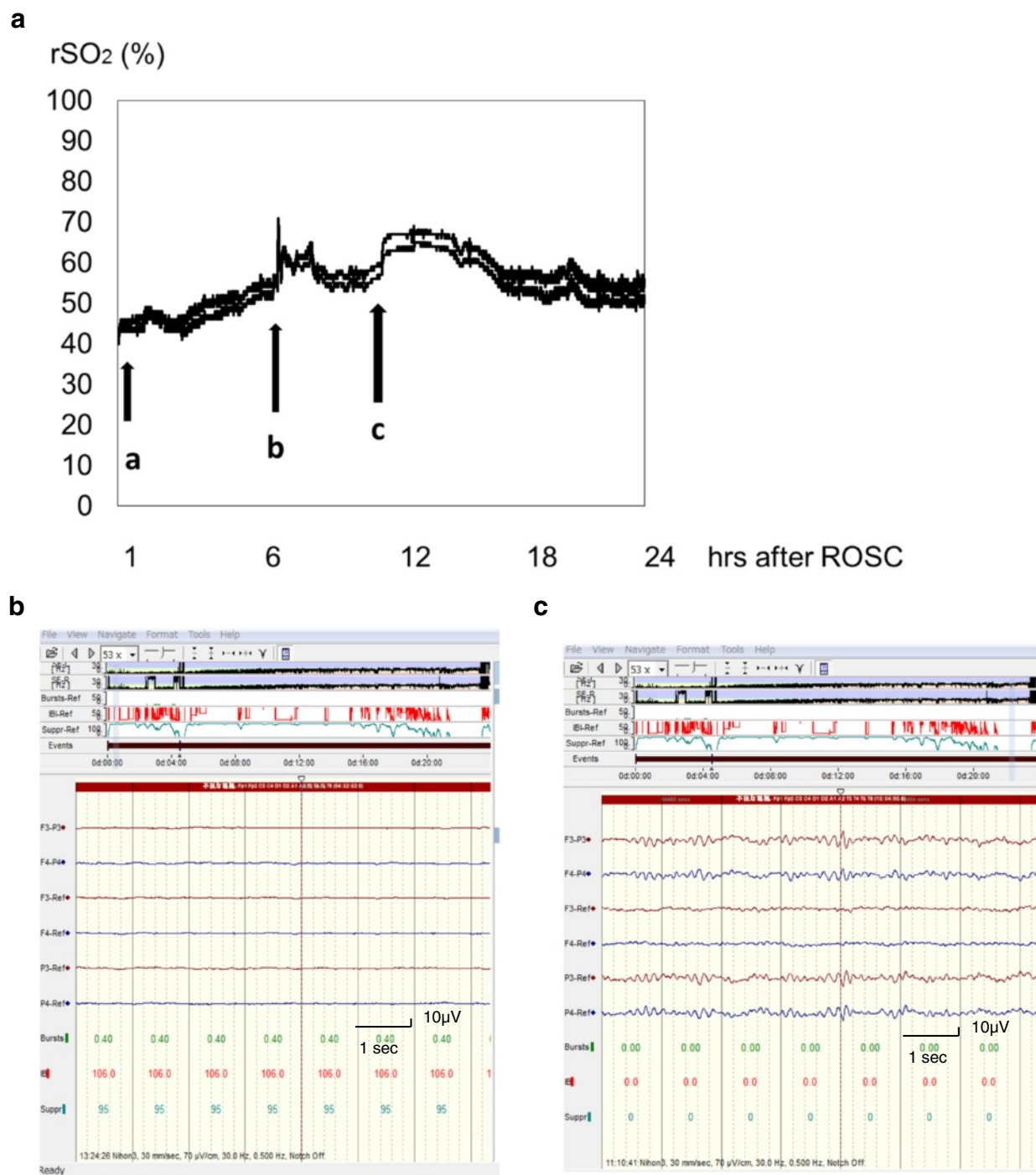
### Lower $rSO_2$ in the early stage in PCAS

Meanwhile, other factors cause lower  $rSO_2$  values in PCAS. The main causes of low  $rSO_2$  stem from too little oxygen supply to meet the cerebral oxygen demand, a sign of cerebral ischemia caused by unstable hemodynamics, hypoxia, or decreased  $PaCO_2$  rather than a cerebral metabolic suppression. Physicians will be able glean hints for the next steps in their treatment strategies for conditions of these types. Good neurological outcome may be obtainable after PCAS if two conditions are met: first, the patient shows no drastic elevation of  $rSO_2$  accompanying an extremely low voltage on the initial EEG; second, the patient shows and no sign of electrographic status epilepticus (Fig. 2) or a suppression-burst pattern (Fig. 3), especially in the early post-resuscitation phase [6].

A second cause of lower  $rSO_2$  values is the continuation of a no-reflow phenomenon suffered by the brain, which is characterized by lack of reperfusion after cerebral ischemia [16] caused by post-ischemic hypoperfusion, an increase in blood viscosity, a reduction in the caliber of small vessels, or impaired microvascular perfusion [16, 17]. In the results, CBF might be reduced even if blood pressure is within a normal range. Interestingly, no-reflow areas manifested as spotty areas of persistently disturbed recirculation were found to spread from the deep site to the brain surface cortex as the duration of the cardiac arrest increased [16]. This was a point of concern, because the  $rSO_2$  probes are placed over the patient's forehead. We suspect that the presence of a spotty no-reflow area on the brain surface may impede the assessment of the cerebral oxygen metabolism for  $rSO_2$  because it measures the hemoglobin oxygen saturation in the regional forebrain cortex.

### Continuous monitoring for $rSO_2$ performed in conjunction with EEG for a PCAS patient undergoing therapeutic hypothermia

There has been little discussion about the significance of  $rSO_2$  in patients with PCAS who are undergoing therapeutic hypothermia. The normal range of  $rSO_2$  in adult PCAS patients treated with therapeutic hypothermia also



**Fig. 4** Changes in rSO<sub>2</sub> and continuous aEEG pattern in PCAS. A male in his 50s collapsed suddenly while running. He received by-stander CPR and his initial cardiac rhythm indicated ventricular fibrillation. Defibrillation was performed by paramedics (34 min after collapse) and the patient was transferred to our hospital. ROSC was obtained and therapeutic hypothermia initiated immediately following his admission. The initial rSO<sub>2</sub> value was around 45 % after ROSC. The aEEG pattern was flat at 3 h after ROSC (**b**) and shifted to a continuous pattern over the next 21 h (**c**). His final neurological outcome was favorable. **a** rSO<sub>2</sub> (%); **B**: aEEG, 3 h after ROSC; (**c**): aEEG, 24 h after ROSC. Arrows; (**a**): BP 100/54 mmHg, arterial gases: PaCO<sub>2</sub> 32.7 mmHg, pH 7.338; (**b**): BP 182/112 mmHg, arterial gases: PaCO<sub>2</sub> 28.4 mmHg, pH 7.437; (**c**): BP 174/120 mmHg arterial gases: PaCO<sub>2</sub> 36.6 mmHg, pH 7.400. BP: blood pressure; ROSC: return of spontaneous circulation; rSO<sub>2</sub>: regional cerebral oxygen saturation; aEEG: amplitude-integrated electroencephalography

remains uncertain because of the hypothermic reduction of CMRO<sub>2</sub>. The amplitude-integrated electroencephalography (aEEG) in PCAS during therapeutic hypothermia was recently classified into four categories: extremely low voltage (flat; maximum voltage < 5 μV); suppression-burst pattern; electrographic status epilepticus with recurrent epileptic form activity; and continuous EEG [6]. Status epilepticus (Fig. 2) and suppression-burst patterns (Fig. 3) on EEG are suggested to have poor outcomes [4–6]. Patterns of these types could be used to predict extensive brain injury after cardiac arrest [4, 5]. Although the initial continuous aEEG pattern was flat (extremely low voltage), we were interested to observe cases in which the aEEG subsequently shifted to a continuous pattern over the following 24 h of therapeutic hypothermia (Fig. 4) and later went on to obtain a good neurological outcome [6]. During the time EEG is flat in the early stage after ROSC, the rSO<sub>2</sub> values might be reflected by the influences from factors such as blood pressure, CBF, PaCO<sub>2</sub> or no-reflow phenomenon. These result demonstrate that rSO<sub>2</sub> alone is insufficient for predicting neurological outcome after PCAS and that rSO<sub>2</sub> cannot be confirmed to reliably indicate whether CBF and metabolism are coupling or uncoupling in the early stage after ROSC.

## Conclusion

The EEG is extremely suppressed after ROSC and gradually changes to various patterns. CMRO<sub>2</sub> might also be initially depressed while the EEG is suppressed. Given the possible therapeutic implications of continuous rSO<sub>2</sub> monitoring in patients with brain injury, the variations of rSO<sub>2</sub> and potential influences of many factors at this stage made it difficult to determine the clinical significance of rSO<sub>2</sub> in PCAS. Careful assessment of prognosis is necessary when relying solely on rSO<sub>2</sub> as a single monitoring modality.

## Patients consent

Informed consent was obtained from all individual participants included in the study.

This study was approved by the Clinical Research Institutional Review Board (IRB: RK-140613-3) of this hospital.

## Abbreviations

PCAS: Post-cardiac arrest syndrome; rSO<sub>2</sub>: Regional cerebral oxygen saturation; ROSC: Return of spontaneous circulation; EEG: Electroencephalography; CMRO<sub>2</sub>: Cerebral metabolic rate of oxygen; CBF: Cerebral blood flow; aEEG: Amplitude-integrated electroencephalography.

## Competing interests

The authors state that they have no conflict of interest (COI).

## Authors' contributions

K.K. designed, wrote this article. K.K., A.S., and S.I. discussed this comments. K.K. read and approved the final manuscript.

Received: 23 May 2015 Accepted: 28 October 2015

Published online: 11 November 2015

## References

- Ito N, Nishiyama K, Callaway CW, Orita T, Hayashida K, Arimoto H, et al. Noninvasive regional cerebral oxygen saturation for neurological prognostication of patients with out-of-hospital cardiac arrest: a prospective multicenter observational study. *Resuscitation*. 2014;85:778–84.
- Hayashida K, Nishiyama K, Suzuki M, Abe T, Orita T, Ito N, et al. Estimated cerebral oxyhemoglobin as a useful indicator of neuroprotection in patients with post-cardiac arrest syndrome: a prospective, multicenter observational study. *Crit Care*. 2014;18:500.
- Nolan JP, Neumar RW, Adrie C, Aibiki M, Berg RA, Böttiger BW, et al. Post-cardiac arrest syndrome: epidemiology, pathophysiology, treatment, and prognostication. A Scientific Statement from the International Liaison Committee on Resuscitation; the American Heart Association Emergency Cardiovascular Care Committee; the Council on Cardiovascular Surgery and Anesthesia; the Council on Cardiopulmonary, Perioperative, and Critical Care; the Council on Clinical Cardiology; the Council on Stroke. *Resuscitation*. 2008;79:350–79.
- Taccone F, Cronberg T, Friberg H, Greer D, Horn J, Oddo M, et al. How to assess prognosis after cardiac arrest and therapeutic hypothermia. *Crit Care*. 2014;18:202.
- Ben-Hamouda N, Taccone FS, Rossetti AO, Oddo M. Contemporary approach to neurologic prognostication of coma after cardiac arrest. *Chest*. 2014;146:1375–8.
- Rundgren M, Westhall E, Cronberg T, Rosén I, Friberg H. Continuous amplitude-integrated electroencephalogram predicts outcome in hypothermia-treated cardiac arrest patients. *Crit Care Med*. 2010;38:1838–44.
- Kurth CD, Levy WJ, McCann J. Near-infrared spectroscopy cerebral oxygen saturation thresholds for hypoxia-ischemia in piglets. *J Cereb Blood Flow Metab*. 2002;22:335–41.
- Rosner MJ, Rosner SD, Johnson AH. Cerebral perfusion pressure: management protocol and clinical results. *J Neurosurg*. 1995;83:949–62.
- Schwarz G, Litscher G, Kleinert R, Jobstmann R. Cerebral oximetry in dead subjects. *J Neurosurg Anesthesiol*. 1996;8:189–93.
- Smith ML, Bendek G, Dahlgren N, Rosén I, Wieloch T, Siesjö BK. Models for studying long-term recovery following forebrain ischemia in the rat. 2. A 2-vessel occlusion model. *Acta Neurol Scand*. 1984;69:385–401.
- Beckstead JE, Tweed WA, Lee J, MacKeen WL. Cerebral blood flow and metabolism in man following cardiac arrest. *Stroke*. 1978;9:569–73.
- Safar P. Cerebral resuscitation after cardiac arrest: research initiatives and future directions. *Ann Emerg Med*. 1993;22:324–49.
- Safar P, Behringer W, Böttiger BW, Sterz F. Cerebral resuscitation potentials for cardiac arrest. *Crit Care Med*. 2002;30:S140–4.
- Cohan SL, Mun SK, Petite J, Correia J, Tavelra Da Silva AT, Waldhorn RE. Cerebral blood flow in humans following resuscitation from cardiac arrest. *Stroke*. 1989;20:761–5.
- Edgren E, Enblad P, Grenvik A, Lilja A, Valind S, Wiklund L, et al. Cerebral blood flow and metabolism after cardiopulmonary resuscitation. A pathophysiologic and prognostic positron emission tomography pilot study. *Resuscitation*. 2003;57:161–70.
- Fischer M, Hossmann KA. No-reflow after cardiac arrest. *Intensive Care Med*. 1995;21:132–41.
- Ginsberg MD, Myers RE. The topography of impaired microvascular perfusion in the primate brain following total circulatory arrest. *Neurology*. 1972;22:998–1011.